



Surgical Treatment of Vaginal Apex Prolapse

Mark D. Walters, MD, and Beri M. Ridgeway, MD

Pelvic organ prolapse is a common problem in women that increases with age and adversely affects quality of life and sexual function. If conservative treatments fail, surgery becomes the main option for symptom abatement. For uterovaginal prolapse, treatment with or without hysterectomy can be offered, and operations must include a specific apical support procedure to be effective. Operations for apical prolapse include transvaginal, open, and laparoscopic or robotic options; few clinical trials have compared the effectiveness and risk of these various surgeries. Grafts can be used selectively for apical suspensions and may improve cure rates but also increase risk of some complications. Slings should be added selectively to reduce postoperative stress incontinence. For women interested in future sexual activity who require apical prolapse surgery, we suggest using transvaginal apical repairs for older patients, those with primary or less severe prolapse, and those at increased surgical risk. We recommend sacral colpopexy with polypropylene mesh (preferably by minimally invasive route) in younger women, those with more severe prolapse or recurrences after vaginal surgery, and women with prolapsed, short vaginas. In older women with severe prolapse who are not interested in sexual activity, obliterative operations are very effective and have high satisfaction rates. An interactive consent process is mandatory, because many decisions—about route of surgery; use of hysterectomy, slings, and grafts; and vaginal capacity for sexual intercourse—require an informed patient's input. Selective referral to specialists in Female Pelvic medicine and Reconstructive Surgery can be considered for complex and recurrent cases.

(*Obstet Gynecol* 2013;121:354–74)

DOI: <http://10.1097/AOG.0b013e31827f415c>

Pelvic organ prolapse (POP) is a common condition in women. Many women are living longer and have a high expectation for quality of life beyond menopause including an active lifestyle and the capacity for sexual activity. Data from the U.S. National Hospital Discharge Survey reported that approximately 200,000 women undergo surgery for POP annually.¹ Pelvic organ prolapse is the surgical indication for approximately 7–14% of all hysterectomies

for benign disease. The prevalence of POP is expected to increase substantially in the coming decades.² The annual number of corrective surgeries and related health care costs will likely increase as well.

The exact causes of POP are unknown and are likely multifactorial. Prolapse can result when defective genital support responds to normal intra-abdominal pressure or when normal pelvic organ supports are subjected chronically to high intra-abdominal pressure. This loss of support occurs as a result of damage to any of the pelvic supportive systems, including the bony pelvis, to which the soft tissues ultimately attach; the subperitoneal retinaculum and smooth muscle component of the endopelvic fascia (the cardinal and uterosacral ligament complex); the pelvic diaphragm, with the levator ani muscles and their fibromuscular attachments to the pelvic organs; and the perineal membrane. The perineal body and the walls of the vagina can also weaken from stretching during childbirth, attenuating changes of aging and menopause, and from genetic and other factors.

Risk factors for the development of prolapse can be classified as predisposing, inciting, promoting, or

From the Section of Urogynecology and Reconstructive Pelvic Surgery, Obstetrics, Gynecology & Women's Health Institute, Cleveland Clinic, Cleveland, Ohio.

Continuing medical education for this article is available at <http://links.lww.com/AOG/A344>.

Corresponding author: Mark D. Walters, MD, Professor and Vice Chair of Gynecology, Obstetrics, Gynecology & Women's Health Institute, 9500 Euclid Avenue, Desk A-48, Cleveland, OH 44195; e-mail: walterm@ccf.org.

Financial Disclosure

Dr. Walters has been a lecturer for American Medical Systems and has performed research for Ethicon Gynecare. The other author did not report any potential conflicts of interest.

© 2013 by The American College of Obstetricians and Gynecologists. Published by Lippincott Williams & Wilkins.

ISSN: 0029-7844/13





decompensating events.² Predisposing factors are genetics, race, and gender that might result in connective tissue defects; inciting factors are pregnancy, childbirth, and surgery such as hysterectomy for prolapse, myopathy, and neuropathy. Promoting factors include obesity, smoking, pulmonary disease, constipation and chronic straining, and recreational or occupational activities; and decompensating factors are aging, menopause, debilitation, and medications. Depending on the combination of risk factors in an individual, prolapse may or may not develop over her lifetime. Advancing age, vaginal childbirth, and obesity are the most established risk factors. Both the Oxford Family Planning Study⁴ and the Women's Health Initiative⁵ showed that vaginal parity was a strong risk factor for POP. The Women's Health Initiative noted that single childbirth was associated with an increased risk of uterine prolapse, and every additional delivery up to five births increased the risk of prolapse by 10–20%.⁵ Established and potential risk factors for POP are shown in Box 1.

The management of POP can be difficult. Several support defects often coexist, and simple anatomic correction of the various defects does not always result in normal function of the vagina and surrounding

organs. Studies demonstrate that a significant proportion of anterior vaginal wall prolapse can be attributed to the descent of the vaginal apex, which clarifies why apical prolapse procedures are critical to correct vaginal prolapse.⁶ The pelvic surgeon must thoroughly understand the interplay of normal and abnormal anatomic support and physiologic function of the pelvic musculature, vagina, bladder, and rectum. The goals of reconstructive pelvic surgery are to restore anatomy, maintain or restore normal bowel and bladder function, and maintain vaginal capacity for sexual intercourse, if desired.

This article discusses the surgical correction of posthysterectomy vaginal apex prolapse and uterovaginal prolapse. We do not directly discuss prolapse of the anterior and posterior vaginal walls (cystocele and rectocele), nor do we address treatment of bladder and anal disorders, which are beyond the scope of this discussion.

DIAGNOSIS AND EXAMINATION

The diagnosis of POP is made using a combination of history and physical examination. Because a majority of women, especially those who are parous, have some degree of pelvic relaxation, it is vital to decipher if women who have prolapse are symptomatic. These symptoms typically include vaginal bulge, pressure, discomfort as well as functional symptoms such as difficulty voiding or defecating, and sexual dysfunction. The simple question, "Do you usually have a bulge or something falling out that you can see or feel in your vaginal area?" is 96% sensitive and 79% specific for prolapse beyond the hymen when used in a pelvic floor disorders population.⁸ Because many cases of POP do not require surgical management, inquiring whether the symptoms of prolapse are bothersome may be helpful in guiding treatment choices.

The physical examination for prolapse should be conducted with the patient in the dorsal lithotomy position. If physical findings do not correspond with symptoms, or if the maximum extent of prolapse cannot be confirmed, the woman can be reexamined in the standing position. A general gynecologic examination is performed to evaluate for coexisting pathology. Levator ani muscle contraction and strength should be noted. After the resting vaginal examination, the patient is instructed to perform a Valsalva maneuver or to cough vigorously to increase the intra-abdominal pressure, which will elicit the physical finding of prolapse. Each vaginal compartment, including the proximal urethra, anterior vaginal wall, vaginal apex or cervix, cul de sac, posterior vaginal wall, and perineum, should be evaluated separately.

Box 1. Established and Potential Risk Factors for Pelvic Organ Prolapse

Established risk factors

Vaginal delivery
Advancing age
Obesity

Potential risk factors

Obstetric factors

- Pregnancy (irrespective of mode of delivery)
- Forceps delivery
- Young age at first delivery
- Prolonged second stage of labor
- Neonatal birth weight greater than 4,500 g

Shape or orientation of bony pelvis
Family history of pelvic organ prolapse
Race or ethnic origin
Connective-tissue disorders or other genetic factors
Occupation entailing heavy lifting
Constipation or other defecation disorder with chronic straining
Previous hysterectomy, especially without concurrent culdoplasty
Selective estrogen-receptor modulators

Modified from The Lancet, 369, Jelovsek JE, Maher C, Barber MD, Pelvic organ prolapse, 1027–38, Copyright 2007, with permission from Elsevier.



The pelvic organ prolapse quantification (POP-Q) examination is validated, has been studied extensively, and allows accurate communication between health care providers and in research protocols.⁹ Using the hymen as a reference point, the POP-Q examination records the genital hiatus length, the perineal body length, the total vaginal length, the amount of cervical or vaginal apex prolapse, and the amount of prolapse of the anterior and posterior vaginal walls. With the exception of total vaginal length, all measurements are taken while the patient is performing a Valsalva maneuver. A split speculum examination is helpful in delineating the individual compartment measurements. For example, half of a speculum is placed over the posterior vaginal wall while the patient bears down so that the anterior vaginal wall prolapse can be accurately measured. For everyday practice, evaluating the maximal amount of prolapse of each compartment (using the hymen as a reference point) may suffice to make surgical decisions and allow accurate communication between health care providers. A rectal examination is required to fully evaluate prolapse of the posterior vaginal wall and perineal body.

Making the diagnosis of vaginal apex prolapse can be challenging in some cases because most patients with apical prolapse also have anterior, posterior, or anterior and posterior vaginal wall prolapse. Identifying the vaginal apex by visualizing the hysterectomy scar can be helpful. Also, placing the examiner's fingers at the apex while the patient is performing a Valsalva maneuver can help confirm the speculum examination findings. Making the correct diagnosis of apical prolapse is tantamount because surgical decision-making often hinges on this finding.

Historically, the terms cystocele, rectocele, and enterocele were used to describe prolapse. However, these terms are less favorable because they imply an unrealistic certainty as to the specific organs behind the vaginal wall. Figure 1 demonstrates the importance of a systematic examination to determine pelvic support defects and illustrates how different types of prolapse can have somewhat similar appearances externally. Enterocele (protrusion of the small intestines and peritoneum into the vaginal canal) is not typically treated as a separate disorder because most patients with enterocele also have significant prolapse of other compartments. An isolated enterocele repair rarely corrects all prolapse symptoms and usually additional support procedures are needed. Preferred terminologies include uterine or cervical prolapse, vaginal vault or apical prolapse, anterior vaginal wall prolapse, and posterior vaginal wall prolapse.¹⁰

Ancillary studies such as imaging do not often contribute to the diagnosis or treatment of POP. Interesting anatomic information can be gleaned from pelvic magnetic resonance imaging or ultrasonography, but this has not been shown to lead to improved treatment outcomes. Radiologic studies such as defecography can aid in the diagnosis and treatment of women with prolapse and defecation disorders.

Many women with POP have urinary incontinence. Those who do not have incontinence are at risk for de novo stress urinary incontinence when their prolapse is corrected. De novo stress urinary incontinence occurs when a previously continent patient develops symptoms of stress urinary incontinence after prolapse repair. This occurs because the previously obstructed urethrovesical junction is straightened by elevating the vaginal apex and anterior vaginal wall, thus unmasking occult stress urinary incontinence. Adding an anti-incontinence procedure at the time of prolapse repair significantly reduces the incidence of stress urinary incontinence.^{11,12} Preoperative office testing helps to decide this issue. Patients with a positive standing cough stress test with a full bladder and the prolapse reduced most likely benefit from a concomitant anti-incontinence procedure.¹² The results of this test are used to counsel the patient preoperatively regarding adding a concomitant anti-incontinence procedure as well as risks of postoperative stress urinary incontinence, sling complications, and postoperative urinary retention.

SELECTING THE TYPE OF SURGERY FOR PELVIC ORGAN PROLAPSE

Women presenting with bothersome POP have a number of treatment options. A careful discussion of the condition and its relationship to bladder, vaginal, and anorectal function should take place. Treatment options include observation, conservative treatments, and surgery.¹³ Conservative treatments such as intensive pelvic muscle (Kegel) exercises and pessaries should be offered. Vaginal estrogen may improve symptoms of atrophy and some of the urinary symptoms but will not improve the structural problems related to prolapse. After careful counseling, and if the patient no longer is improved by or does not desire conservative therapies, then surgical correction should be considered.

We believe surgical treatment of POP should always address all of the segments of the vagina that are involved in the prolapse and an attempt should be made to improve related visceral function of the lower urinary tract, vagina, and anorectum. Transvaginal hysterectomy alone (without apical prolapse repair) is

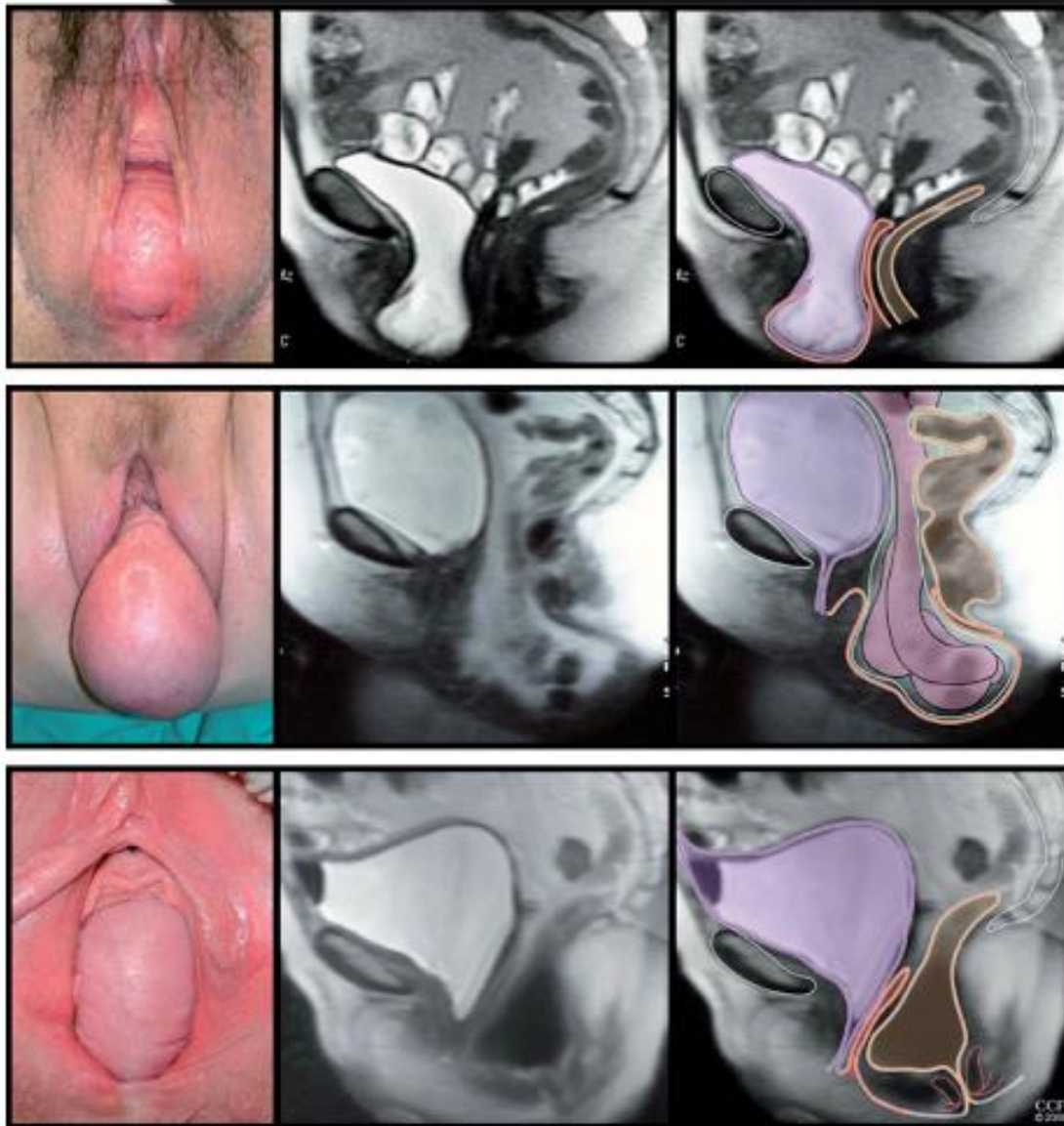


Fig. 1. Photographs in the lithotomy position and sagittal magnetic resonance image showing vaginal wall prolapse. Prolapse might include (top to bottom): bladder (cystocele), small bowel (enterocele), or rectum (rectocele). Color codes include purple (bladder), orange (vagina), brown (colon and rectum), and green (peritoneum). Reprinted from *The Lancet*, 369, Jelovsek JE, Maher C, Barber MD, Pelvic organ prolapse, 1027–38, Copyright 2007, with permission from Elsevier. Walters. *Surgical Treatment of Vaginal Apex Prolapse*. *Obstet Gynecol* 2013.

not an appropriate operation to treat significant uterovaginal prolapse. Once the patient elects surgery, the surgeon and patient have a number of issues to consider: 1) Is the patient sexually active and is she interested in having vaginal intercourse in the future? 2) If the uterus is present, should a hysterectomy be done at the time of her prolapse repair? 3) Should the prolapse repair be done through the transvaginal or abdominal route and, if abdominally, should it be done using laparotomy, laparoscopy, or robotic assistance? 4) Can the prolapse surgery be done by repairing the patient's own native tissues or is a graft

necessary to suspend the apex or other segments of the vaginal walls? 5) Is a concurrent procedure to correct overt or occult stress urinary incontinence necessary? 6) Should I refer this surgery to a specialist in Female Pelvic Medicine and Reconstructive Surgery? A discussion of these questions is provided in Box 4.

PREOPERATIVE CONSIDERATIONS

We recommend starting vaginal estrogen in postmenopausal women with vaginal atrophy at least 4–6 weeks before surgery for prolapse. Tissue integrity improves with estrogen and this may provide clinical benefits to



the patient. No studies have been done, however, showing improved outcomes by using estrogen before, after, or before and after prolapse surgery.¹⁴

Informed consent should be methodical; it is a process rather than a single event. In addition to discussing the usual risks encountered in a major operation (infection, hemorrhage, injury to adjacent organs, and medical and anesthesia complications), a frank conversation should take place regarding the expected outcomes, the likelihood of prolapse recurrence, the potential of urinary incontinence, and the possibility of dyspareunia. Additionally, if the use of a mesh or graft is planned, delineating the unique set of risks related to these procedures is prudent (Box 1).

All patients require perioperative prophylactic antibiotics and efforts to prevent venous thromboembolic events. Antibiotics should be given within 60 minutes of incision to achieve minimal inhibitory concentrations in the skin and tissues by the time the incision is made. This typically means a first-generation cephalosporin (cefazolin) or combination regimens (500 mg metronidazole and 400 mg ciprofloxacin) if the patient has an allergy to penicillin.¹⁵ In general, all patients undergoing apical prolapse surgery are at moderate risk for thromboembolic events and require a prevention strategy.¹⁶ Low-dose unfractionated heparin (5,000 units every 12 hours) or low-molecular-weight heparins (eg, 40 mg enoxaparin or 2,500 units of dalteparin), an intermittent pneumatic compression device, or a combination of these are recommended. Either form of heparin should be started 2 hours before surgery and the compression stockings placed on the patient in the operating room before incision. These treatment approaches should be continued until the patient is ambulatory.

The value of preoperative bowel preparation has been challenged in a meta-analysis.¹⁷ Additionally, mechanical bowel preparations may increase harm by causing relative dehydration and potential contamination of the surgical field with liquid stool. Therefore, except in unusual circumstances in which bowel surgery is planned, we do not recommend bowel preparation before surgeries for POP.

TRANSVAGINAL PROCEDURES THAT SUSPEND THE APEX WITHOUT A GRAFT

All of the transvaginal surgeries are done in the supine lithotomy position with the legs elevated in either high cane stirrups or in Allen stirrups. Leg elevation with the buttocks at the end of the table facilitates deep vaginal surgery and the use of two surgical assistants. However, care should be taken to not flex the hips to beyond 90° to keep the risk of nerve compression injury as low as possible. Which transvaginal support

procedure to use tends to be based on the training and expertise of the operating gynecologist. The concurrent use of vaginal hysterectomy, the shape and depth of the vagina, and the severity of the prolapse also influence the surgeon somewhat. Few data are available comparing the transvaginal repairs for efficacy.

Modified McCall Culdoplasty

When mild forms of uterovaginal prolapse are present, vaginal hysterectomy and culdoplasty with appropriate vaginal repairs are usually sufficient to relieve the patient's symptoms and restore normal vaginal function. Suturing the uterosacral ligaments more proximally, the so-called "high McCall" procedure, is used by some vaginal surgeons in place of the uterosacral ligament colpopexy. Addition of a McCall culdoplasty is also effective for prophylaxis against future vaginal apical prolapse.¹⁸ The advantage of the McCall culdoplasty is that it not only closes the redundant cul-de-sac and associated enterocele, but it also provides apical support and lengthening of the vagina. Many authorities advocate using this procedure as part of every vaginal hysterectomy, even in the absence of prolapse, to minimize future formation of apical prolapse.

The technique of this repair is as follows: 1) After the vaginal hysterectomy, the uterosacral ligaments are tagged, held, and placed under tension. The deep cul-de-sac is palpated and excised if very large; 2) one to three modified McCall stitches are placed intraperitoneally with a permanent suture. Each suture incorporates the left distal uterosacral ligament, the cul-de-sac peritoneum over the rectum, and the right distal uterosacral ligament. An additional distal suture is placed using delayed absorbable suture, and the ends are passed through the midline of the posterior vaginal wall (Fig. 2); and 3) sutures are then tied, resulting in fixation of the vaginal apex to the distal portion of the endopelvic fascia as well as high closure of the cul-de-sac peritoneum. When there is excessive redundancy of the posterior vaginal wall and peritoneum, a modification of the McCall culdoplasty in which a wedge of posterior vaginal wall and peritoneum are excised can be considered.

Sacrospinous Ligament and Ileococcygeus Colpopexy

To perform these procedures correctly and safely, the surgeon must be familiar with pararectal anatomy as well as the anatomy of the ischial spine, ileococcygeus and coccygeus muscles, sacrospinous ligament, and surrounding vascular and nerve structures (Fig. 3). The sacrospinous ligaments extend from the ischial spines on each side to the lower portion of the sacrum and coccyx. The fibromuscular coccygeus muscle and

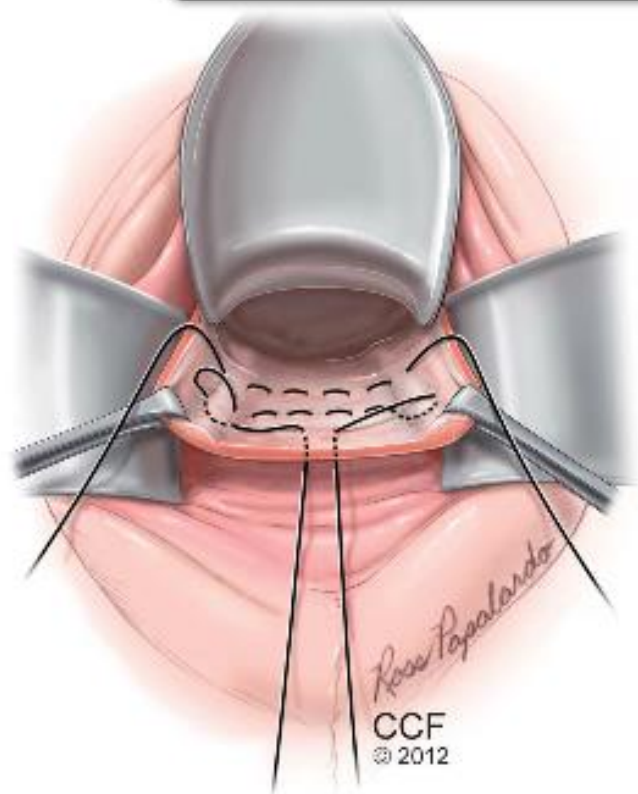


Fig. 2. McCall culdoplasty technique. Internal and external McCall sutures are placed. The lowest suture (external McCall) incorporates the posterior vaginal wall, providing additional support. Illustration by Ross Papalardo. Reprinted with permission, Cleveland Clinic Center for Medical Art & Photography © 2010–2012. All rights reserved.

Walters. *Surgical Treatment of Vaginal Apex Prolapse. Obstet Gynecol* 2013.

sacrospinous ligament are basically the same structure and thus can be called the coccygeus–sacrospinous ligament. The coccygeus muscle has a large fibrous component in the body of the muscle and on the anterior surface, where it appears as white ridges. The coccygeus–sacrospinous ligament is identified by palpating the ischial spine and tracing the flat triangular thickening medial and posterior to the sacrum.

Posterior to the coccygeus–sacrospinous ligament are the gluteus maximus muscle and the fat of the ischioanal fossa. The pudendal nerves and vessels lie lateral and directly posterior to the ischial spine. The sciatic nerve lies superior and lateral. Superiorly and behind the coccygeus–sacrospinous ligament lies an abundant vascular supply that includes inferior gluteal vessels and hypogastric venous plexus.

Before the sacrospinous ligament colpopexy is initiated, one should have preoperatively recognized the ischial spines and coccygeus–sacrospinous ligament on pelvic examination. The sacrospinous liga-

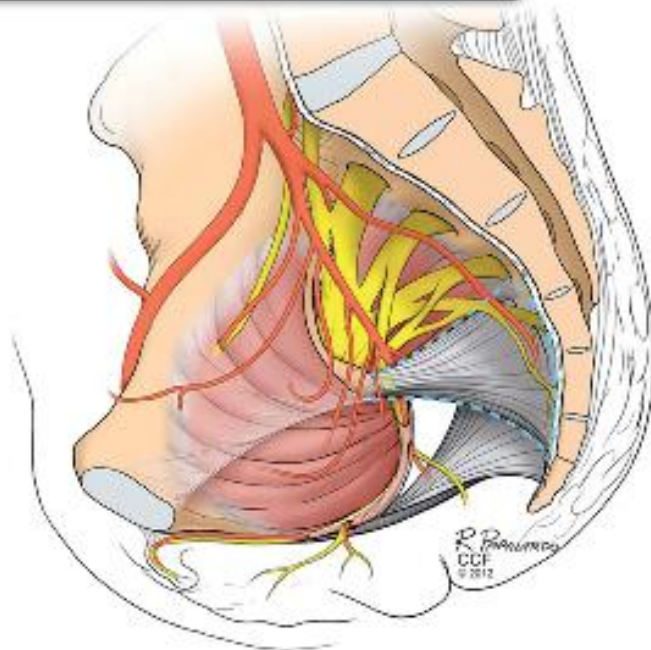


Fig. 3. Close-up view of the anatomy of the right coccygeus–sacrospinous complex to demonstrate close proximity of various nerves and blood vessels. Illustration by Ross Papalardo. Reprinted with permission, Cleveland Clinic Center for Medical Art & Photography © 2010–2012. All rights reserved.

Walters. *Surgical Treatment of Vaginal Apex Prolapse. Obstet Gynecol* 2013.

ment colpopexy is done for moderate-to-severe posthysterectomy apical prolapse; it can also be done with simultaneous vaginal hysterectomy or even as a hysteropexy. We usually perform the apical suspension unilaterally to the right coccygeus–sacrospinous ligament, but surgeons occasionally use the left coccygeus–sacrospinous ligament or do a bilateral suspension. The performance of this operation usually requires simultaneous correction of the anterior and posterior vaginal walls and an enterocele repair. Placing the prolapsed vaginal apex to the sacrospinous ligament to see whether the vagina is long enough to complete the repair and whether the anterior and posterior vaginal wall prolapse disappears helps to determine whether cystocele and rectocele repairs are needed. The patient should be routinely consented for these repairs because many times it is difficult to discern the extent of the various defects in the office.

The technique of unilateral sacrospinous colpopexy is as follows: 1) if the uterus is present, a vaginal hysterectomy is done and the peritoneum closed to perform an extraperitoneal approach. Sacrospinous cervicopexy or hysteropexy could also be done if desired using similar technique; 2) the apex of the vagina is grasped with two Allis clamps. Downward traction is used to determine the extent of prolapse of

the apex, anterior, and posterior vaginal walls. The vaginal apex is then reduced to the sacrospinous ligament intended to be used. At times the true apex of the vagina at the hysterectomy scar is foreshortened and will not reach the intended area of fixation, like with a shortened anterior vaginal wall and a prominent posterior enterocele. The “new” apex should be moved to a portion of the vaginal wall over the most severe prolapse, thus allowing sufficient vaginal length for suspension to the coccygeus–sacrospinous ligament. The intended apex is tagged with two sutures for its later identification; 3) access to the coccygeus–sacrospinous ligament can be through a posterior vaginal dissection, through the apex, or by an anterior approach dissecting at the base of a paravaginal dissection. In the posterior approach, a midline posterior vaginal wall incision is made just short of the apex of the vagina, leaving a small vaginal bridge approximately 3 or 4 cm wide. In the majority of cases, an enterocele sac is present. This sac should be dissected off the rectum and posterior vaginal wall and apex, the peritoneum entered, and the sac closed with a high pursestring suture; 4) the perirectal space or the space along the peritoneum near the apex is then entered by breaking through the areolar tissue just lateral to the enterocele sac at the level of the ischial spine. This can usually be accomplished with blunt dissection after mobilizing the rectum medially. At times, however, the use of gauze on the index finger or a tonsil clamp

is necessary to break into this space; 5) after entry into the perirectal space, palpate the ischial spine and, with dorsal and medial movement of the fingers, the entire coccygeus–sacrospinous ligament. Blunt dissection is used to further remove tissue from this area. The surgeon should take great care to ensure that the rectum is adequately retracted medially. At this time, we recommend performing a rectal examination to ensure that no inadvertent rectal injury has occurred; 6) several techniques are used for the actual passage of sutures through the ligament. Our preferred technique for passing the sutures through the coccygeus–sacrospinous ligament uses a transvaginal suture-capturing device (Fig. 4A). The proposed advantage of this technique is that it is safer and easier because the device enters the coccygeus–sacrospinous ligament under direct palpation of distinct landmarks, proceeding top to bottom, and is then pulled down into the safe perirectal space below. Other popular instruments to place the coccygeus–sacrospinous ligament sutures are the long-handled Deschamps ligature carrier and nerve hook, the Miya hook, and even direct suturing.

To perform this technique on the right, the left middle fingertip is placed on the coccygeus–sacrospinous ligament just below its superior margin, approximately 3 cm medial to the ischial spine or in the midposition of the coccygeus–sacrospinous ligament. A long retractor such as a Breisky-Navratil retractor can be placed medially to mobilize and

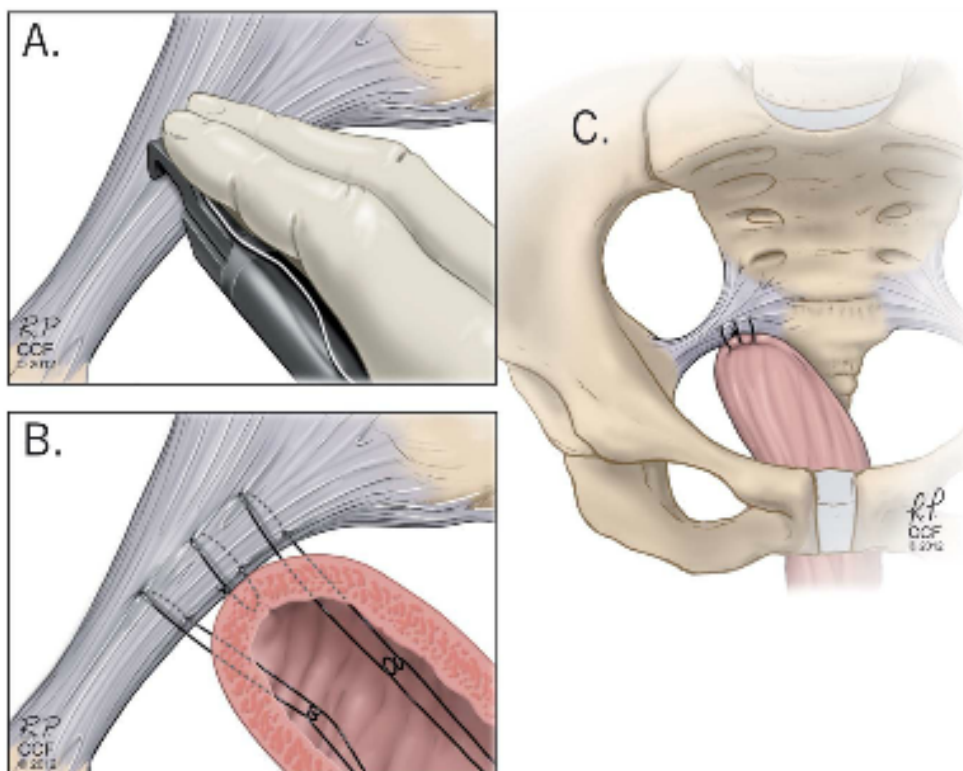


Fig. 4. Sacrospinous ligament colpopexy. **A.** Passage of transvaginal suture-capturing device with suture through the coccygeus–sacrospinous ligament. Note the needle tip is passed from above to downward. **B.** Three sutures are placed through the coccygeus–sacrospinous ligament; the middle suture is nonabsorbable so is through the muscularis and the knot buried. **C.** Final attachment of the vagina to the coccygeus–sacrospinous ligament. Illustration by Ross Papalardo. Reprinted with permission, Cleveland Clinic Center for Medical Art & Photography © 2010–2012. All rights reserved.

Walters. *Surgical Treatment of Vaginal Apex Prolapse*. *Obstet Gynecol* 2013.



protect the rectum if needed. Great care should be taken when retracting in this area to prevent bleeding and nerve and rectal damage. The suture-capturing device, in the right hand in a closed position, is slid along the palmar surface of the left hand. With the tip of the middle finger, the suture-capturing device notch is placed 3 cm medial to the ischial spine, approximately 0.5 cm below the superior edge. With the middle and index fingers, apply firm pressure downward and engage the device at the handle so the needle passer penetrates the coccygeus-sacrospinous ligament (Fig. 4A). Release the handle and remove the device with the suture and tag the suture. Depending on the size of the ligament, most authorities place between two and four sutures through the coccygeus-sacrospinous ligament to attach to the vaginal apex (Fig. 4B). There is no consensus about suture type; a combination of delayed absorbable and non-absorbable monofilament sutures is commonly used; 7) if the patient requires an anterior vaginal wall repair, we prefer performing an anterior colporrhaphy at this point in the operation; 8) the surgeon then brings the stitches out to the apex of the vagina, either with the use of a pulley stitch for permanent sutures or simply passing each pair of sutures through the apex for delayed absorbable sutures (Fig. 4B). After the sutures have been brought out through the vagina, the upper portion of the posterior vaginal wall is closed with continuous No. 2-0 absorbable sutures. The vaginal apex suspension stitches then are tied, thus elevating the apex of the vagina to the coccygeus-sacrospinous ligament (Fig. 4C). It is important that the vagina comes into contact with the coccygeus-sacrospinous ligament and no suture bridge exists, especially if delayed absorbable sutures are being used. While tying these sutures, it may be useful to perform a rectal examination to detect any suture bridges; 9) after these sutures are tied, an anti-incontinence procedure (if needed) and a posterior colpoperineorrhaphy are completed, as needed. The vagina is packed with a moist gauze for 24 hours, if desired; and 10) the risk of ureteral obstruction or kinking is extremely low with sacrospinous ligament colpopexy. However, cystourethroscopy should be used if a concomitant enterocele repair, anterior colporrhaphy, or anti-incontinence procedure is performed.

In older women who are having transvaginal colpopexy, if the vagina is not long enough to reach either coccygeus-sacrospinous ligament or if scarring makes it not possible or unsafe to suture into the coccygeus-sacrospinous ligament, then bilateral fixation of the prolapsed vaginal apex to the iliococcygeus fascia just below the ischial spines is a useful and

effective technique. It also can be used if the vagina is somewhat foreshortened, but the posterior apex needs additional support during rectocele repair. The technique of this repair involves identifying areas 1–2 cm distal and posterior to the ischial spines in the ileococcygeus muscles and fasciae on each side. We place a single No. 0 delayed absorbable suture deeply into the levator muscle and fascia bilaterally. Both ends of each suture are passed through the ipsilateral posterior vaginal apex and held with a hemostat. The posterior colporrhaphy is then completed, the vagina is closed, and both sutures are tied, elevating the posterior vaginal apex.

Uterosacral Ligament Colpopexy

Another transvaginal approach to the management of apical prolapse is the bilateral uterosacral ligament colpopexy. This surgery is popular in the United States, and it can be performed vaginally, abdominally, or laparoscopically. An advantage is that it suspends the apex of the vagina to the endopelvic fascia, directing it in the midline to the hollow of the sacrum, and thus does not create any significant distortion of the vaginal axis. The technique is as follows: 1) a vaginal hysterectomy is completed and the uterosacral ligaments tagged. If the uterus was previously removed, the vaginal apex is grasped with two Allis clamps and incised with a scalpel. The vaginal epithelium is dissected off the enterocele sac, and the enterocele is opened. If access cannot be obtained, one may consider performing an extraperitoneal uterosacral ligament colpopexy; 2) several moist tail sponges are placed in the posterior cul-de-sac. A wide Deaver or Breisky retractor is used to elevate the packs and the intestines out of the operative field; 3) the ischial spines are palpated transperitoneally. The remnants of the uterosacral ligaments are found posterior and medial to the ischial spine, and the ureter can sometimes be palpated or visualized along the pelvic side wall anywhere from 2–5 cm ventral and lateral to the ischial spine; 4) traction on Allis clamps placed on the distal vaginal edges at approximately 5 and 7 o'clock allows easy palpation of the uterosacral ligaments. We usually place a long Allis clamp on the proximal uterosacral ligament just lateral to the rectum to help identify strong tissue for suture placement (Fig. 5A); 5) two to three delayed absorbable or nonabsorbable sutures are passed through the ligament on each side (Fig. 5B). To assure adequate vaginal length, the highest suture should be at least to the level of the ischial spine. It is uncertain if nonabsorbable sutures provide higher rates of cure; they do however result in more suture erosions¹⁹; 6) the distal remnants of the uterosacral

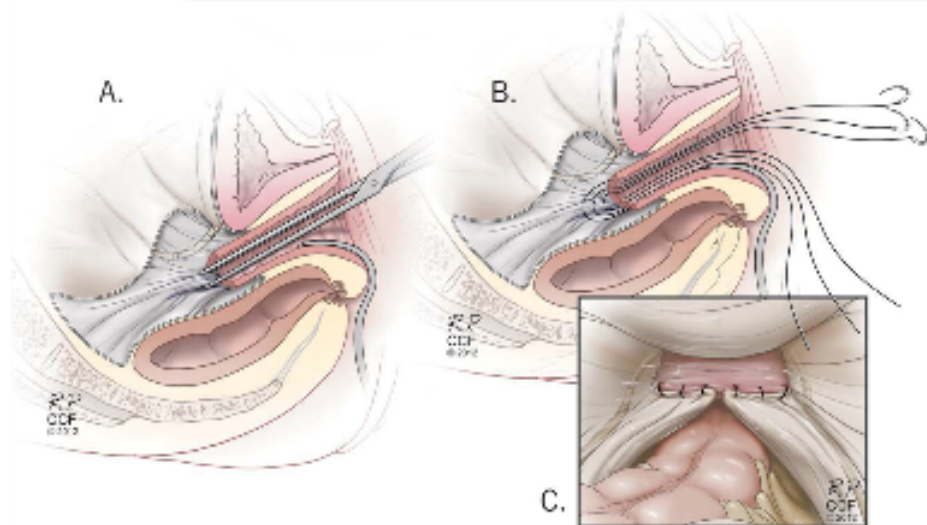


Fig. 5. Uterosacral ligament colpopexy. **A.** The uterosacral ligament at about the level of the ischial spine is grasped with an Allis clamp. **B.** Three sutures are placed through the ipsilateral uterosacral ligament and then through the vaginal apex. **C.** Sutures are placed bilaterally and tied, suspending the apex. Illustration by Ross Papalardo. Reprinted with permission, Cleveland Clinic Center for Medical Art & Photography © 2010–2012. All rights reserved.

Walters. *Surgical Treatment of Vaginal Apex Prolapse*. *Obstet Gynecol* 2013.

ligaments may be plicated across the midline with one to three permanent sutures as described previously, if desired, thus obliterating the cul-de-sac; 7) if necessary, an anterior colporrhaphy is performed and the anterior vaginal epithelium is closed; 8) the delayed absorbable sutures that had been passed high up through the uterosacral ligaments are then passed through the full thickness of the anterior and posterior vaginal walls at the apex (Fig. 5B); 9) the vagina is trimmed and closed with a No. 2-0 delayed absorbable suture; 10) tying of the apical suspension sutures elevates the vagina high up into the hollow of the sacrum (Fig. 5C); and 11) cystoscopy is performed after administration of indigo carmine to assure ureteral patency.

Obliterative Procedures

If the patient is older and no longer sexually active and does not have plans to have vaginal intercourse in the future, a vaginal obliterative procedure may be appropriate. Obliterative procedures can be performed for posthysterectomy vaginal apex prolapse (partial colectomy) and uterovaginal prolapse (Le Fort colpoceleisis). The uterus can be left in situ like with the Le Fort procedure or a concurrent hysterectomy can be done before a colectomy; both options are associated with a relatively quick operative time and low morbidity. These procedures significantly narrow and shorten the vagina; they have a very low rate of prolapse recurrence and are associated with high patient satisfaction.²⁰

For patients with posthysterectomy vaginal vault prolapse, a partial colectomy and colpoceleisis can be done to effectively treat the prolapse. The technique is as follows: 1) to perform this operation for complete vaginal vault eversion, the prolapse is separated into

panels using a marking pen (Fig. 6A). The vaginal epithelium is infiltrated with dilute local anesthetic and epinephrine. A scalpel or electrocautery device is used to score the vaginal epithelium; 2) the vaginal epithelium is completely excised from the underlying vaginal muscularis and endopelvic fascia (Fig. 6B). The surgeon should leave the maximum amount of muscularis behind on the bladder and rectum. No attempt is made to enter the enterocele sac if present. Hemostasis is an absolute must. A 2-cm to 3-cm rim of epithelium is left circumferentially in the vagina just inside the hymen; 3) a series of purse-string sutures are used to invert the prolapsed tissue (Fig. 6C). We place the most distal suture first and the surgical assistant reduces the tissue in the center of the purse-string cephalad while the surgeon ties the purse-string suture. A hemostat is placed at the knot of the suture and an additional purse-string is placed and tied. Three to five purse-string sutures of delayed absorbable or permanent monofilament suture are typically required to reduce a large prolapse; 4) a small anterior colporrhaphy is performed if needed; 5) to reduce the genital hiatus, a large diamond of vaginal epithelium is removed from the posterior vaginal wall and introitus; 6) a posterior colporrhaphy, levator plication, and aggressive perineorrhaphy are performed and the vagina closed (Fig. 6D); 7) a sling (if indicated) is performed; and 8) we recommend routine cystoscopy after intravenous injection of indigo carmine to document ureteral patency.

For patients with uterovaginal prolapse who do not desire hysterectomy or for those in whom hysterectomy is too risky, the technique of Le Fort colpoceleisis is appropriate. Traction is placed on the cervix to evert the vagina, and the vaginal epithelium is

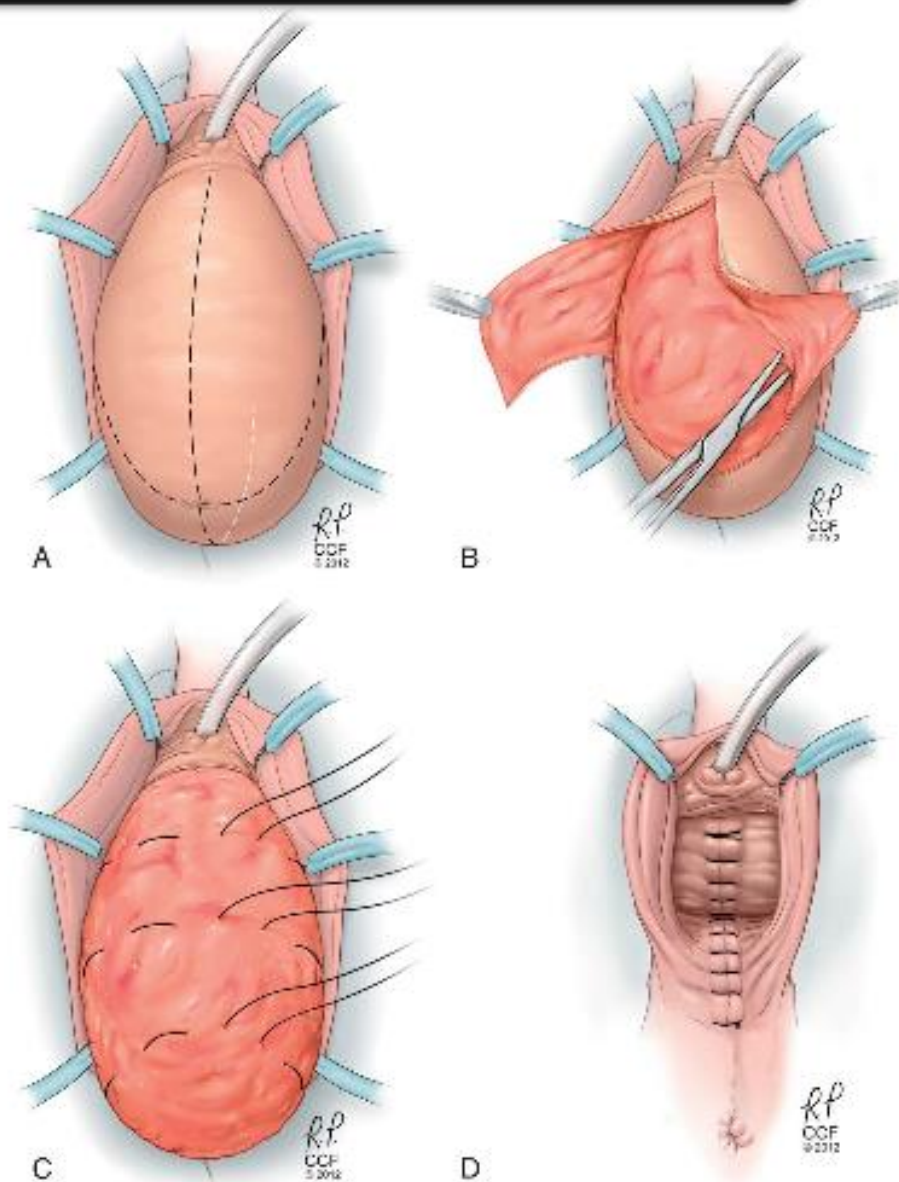


Fig. 6. Posthysterectomy partial colpocleisis. **A.** The prolapse is separated into panels using a marking pen or electro-surgical device. **B.** The vaginal epithelium is completely excised from the underlying vaginal muscularis and endopelvic fascia. **C.** Purse-string sutures are used to invert the prolapsed tissue. **D.** Posterior colporrhaphy, levator plication, and perineorrhaphy are performed as needed and the vagina closed. Illustration by Ross Papalardo. Reprinted with permission, Cleveland Clinic Center for Medical Art & Photography © 2010–2012. All rights reserved.

Walters. *Surgical Treatment of Vaginal Apex Prolapse*. *Obstet Gynecol* 2013.

injected with dilute local anesthetic and epinephrine just below the epithelium. A Foley catheter with a 10-mL balloon is placed in the bladder for identification of the bladder neck. A marking pen is used to mark out anterior and posterior panels that mirror each other and are to be de-epithelialized. Anteriorly this extends 2 cm from the tip of the cervix to 4–5 cm below the external urethral meatus. The marked areas are removed by sharp dissection. After reducing the cervix, the cut edges of the anterior and posterior vaginal walls are sewn together with interrupted delayed absorbable sutures, creating epithelium-lined tunnels bilaterally. The uterus and vaginal apex thus are gradually turned inward. After the vagina has been inverted, the superior and inferior margins of the incisions are sutured together. A perineorrhaphy with

a distal levator plication should be done to narrow the introitus and build up the perineum.²⁰

OUTCOMES OF TRANSVAGINAL PROCEDURES

Although there is a wealth of experience and observational studies on transvaginal repair of apical prolapse, there are surprisingly few high-quality cohort studies with long follow-up or randomized trials comparing the different transvaginal repairs. The results of McCall culdoplasty were discussed in a review article by Sze and Karram.²¹ Of the early studies reporting 367 patients, 322 (88%) received postoperative follow-up ranging from 1 to 12 years with a cure rate of 88–93%. A subsequent study by Webb et al²² reported results on 660 women, most of whom were followed up with



a questionnaire. Approximately 12% of patients complained of a “bulge” or “protrusion” at the time of questioning, 82% indicated that they were satisfied, and 22% of sexually active women reported dyspareunia.

Early cohort studies of sacrospinous ligament and ileococcygeus colpopexy show the operations to be effective for vaginal apex support, but vaginal prolapse recurs with time, most commonly the anterior wall. With a 73-month follow-up in 243 patients who had had sacrospinous ligament colpopexy and vaginal repairs, Paraiso et al²³ showed prolapse recurrence in the anterior, posterior, and apical segments to be 37.4%, 13.6%, and 8.2%, respectively. Prolapse-free survival rates at 1, 5, and 10 years were 88.3%, 79.7%, and 51.9%, respectively. From 1981 to 1993, Shull et al²⁴ and Meeks et al²⁵ used the iliococcygeus colpopexy technique to treat 152 patients with post-hysterectomy vault prolapse or total uterine prolapse. Thirteen (8%) patients developed recurrent pelvic support defects at various sites 6 weeks to 5 years after the initial procedure; two had apical prolapse, eight had anterior vaginal prolapse, and three had posterior wall defects. In 2001, Maher et al²⁶ performed a matched case-control study to compare ileococcygeus suspension and sacrospinous colpopexy for vaginal vault prolapse. They found the procedures to be equally effective with similar complication rates.

In 2000, Shull and colleagues²⁷ reported on their experience with 298 patients after uterosacral ligament colpopexy. Twelve percent had evidence of an anterior wall defect in the form of cystocele or urethrocele and 4% of patients developed posterior wall defects. In all, 38 patients (13%) had development of one or more support defects. A more recent systematic review of uterosacral ligament colpopexy showed that, in the anterior, apical, and posterior vagina, the pooled rates for successful anatomic outcome were 81.2%, 98.3%, and 87.4%, respectively. Patients with more severe POP (stage III or IV) had significantly worse cure rates.²⁸

After an obliterative procedure, approximately 90–95% of patients have relief of prolapse symptoms and good anatomic results.^{20,29,30} The morbidity associated with the surgery is largely related to the health status of the elderly affected patients.

The recent Cochrane Review on surgical management of POP does not provide much additional outcome information about efficacy of transvaginal prolapse repairs because there are so few randomized surgical trials addressing these surgeries.³¹ The systematic review by Diwadkar et al³² showed that transvaginal prolapse repairs without mesh, compared with sacral colpopexy and mesh-augmented vaginal repairs,

have the highest rate of reoperation for prolapse recurrence but the lowest overall reoperation rate. This is because the transvaginal repairs are relatively safe and few related complications require reoperation.³²

COMPLICATIONS OF TRANSVAGINAL PROCEDURES

All of the transvaginal surgeries involve dissection of vesicovaginal and rectovaginal spaces and thus have small risks of bleeding and of cystotomy and proctotomy. Postoperatively, vaginal or pelvic infections, voiding difficulties, and urinary tract infections can occasionally occur but are short-lived. The most worrisome complication with McCall culdoplasty, uterosacral ligament colpopexy, and colectomy or colpocleisis is ureteral injury or kinking. The risk is approximately 2–4%, and most obstructions are relieved intraoperatively if recognized at cystoscopy. It is imperative that intraoperative cystoscopy is performed after tying the colpopexy sutures to ensure ureteral patency. If ureteral spill is not observed, then the suspension sutures on that side should be cut and removed and the ureter reevaluated. Often, the suture can be replaced using a more medial placement into the uterosacral ligament complex.

Unique but serious intraoperative complications can occur, especially with sacrospinous colpopexy. Potential complications of the procedure include hemorrhage, nerve injury, and rectal injury. Severe hemorrhage with blood transfusion can result from overzealous dissection superior to the coccygeus muscle or ischial spine. This can result in hemorrhage from the inferior gluteal vessels, hypogastric venous plexus, or pudendal vessels. Hemorrhage from these vessels can be difficult to control. For this reason, we prefer limited careful dissection on top of (but not behind) the coccygeus-sacrospinous ligament. We also use the transvaginal suture-capturing device technique in which the needle tip is passed downward toward the muscle rather than the technique using the Deschamps ligature carrier in which the needle tip is passed superiorly toward the vasculature. If severe bleeding occurs in the area around the coccygeus muscle, we recommend initially packing the area. If this does not control the bleeding, then visualization, attempted ligation with clips or sutures, and use of thrombin products should be performed. This area is difficult to approach transabdominally or with selective embolization, so bleeding should be controlled vaginally, if possible.

Moderate-to-severe buttock pain on the side on which the sacrospinous suspension was performed can occur; this has also been reported after high



uterosacral suspension. This is probably caused by compression or injury of a small nerve that runs through the coccygeus-sacrospinous ligament. The buttock pain is almost always self-limiting and should resolve completely by 6 weeks postoperatively. Reassurance and anti-inflammatory agents usually are all that are necessary. Because of the close proximity of the pudendal nerves (and vessels) to the lateral coccygeus-sacrospinous ligament, the potential for injury is present so dissection and suturing should avoid the ischial spine. If pudendal nerve injury occurs with postoperative symptoms of unilateral vulvar pain, numbness, or pain and numbness, immediate reoperation with removal of offending suture material may be necessary.

Rectal examination should be performed frequently during all transvaginal repairs because of the close proximity of the rectum to vaginal dissection and colpexy sutures. Rectal injury can occur during entering of the perirectal space as well as during mobilization of tissue off of the coccygeus-sacrospinous ligament. If a rectal injury is identified, it can usually be repaired primarily transvaginally by conventional techniques. Small bowel obstruction has also been reported after transvaginal colpexy but is rare.

Vaginal stenosis and dyspareunia can occur if too much anterior and posterior vaginal wall tissue is trimmed, if the vagina is left too short, or if too tight a posterior colporrhaphy is performed. We recommend postoperative use of estrogen vaginal cream in these patients in the hope of preventing or decreasing the incidence of this problem.

TRANSVAGINAL MESH PROCEDURES

In 2004, prepackaged kits to place mesh transvaginally were introduced. Most kits use trocars to attach mesh or graft to the arcus tendinous fasciae pelvis or sacrospinous ligaments bilaterally. With bilateral attachments, these grafts create a hammock that supports the apex and anterior or posterior walls, depending on placement. The goals of these procedures are to decrease the rate of recurrent prolapse by adding a graft to bolster native tissue and to decrease complications by avoiding intra-abdominal surgery. On introduction into the market, there were many different brands and types of graft kits, yet data for specific prototypes were few.

Given the relatively recent introduction of these procedures, case series and retrospective trials outnumber randomized controlled trials, and the available randomized controlled trials have shorter-term follow-up. Few studies have specifically addressed vaginal apex prolapse and most data detail outcomes after

mesh-augmented repair of the anterior vaginal wall. The largest randomized controlled trial to date comparing anterior colporrhaphy with an anterior mesh kit demonstrated that compared with anterior colporrhaphy, the use of an anterior mesh kit results in improved 1-year objective and subjective outcomes but higher rates of surgical complications and postoperative adverse events including mesh exposure and de novo stress urinary incontinence.³³ The updated Cochrane Review on the subject reviewed outcomes of approximately 4,000 women and revealed that native tissue anterior repair was associated with more anterior compartment failures than polypropylene mesh repair as an overlay or armed transobturator mesh kit, but there were no differences in subjective outcomes, quality-of-life data, or rates of de novo dyspareunia, stress urinary incontinence, or reoperation rates for prolapse or incontinence between groups.³¹

In addition to the complications inherent to all transvaginal prolapse repairs, unique complications related to the mesh or trocars can occur. Mesh-related functional complications such as chronic pelvic pain, leg and groin pain, vaginal pain, and dyspareunia have all been reported. A systematic review that evaluated complications and reoperations after vaginal apex surgical repair demonstrated that the overall rate of reoperation (for complications and for recurrent prolapse) is highest after transvaginal mesh repair.³² Exposure of mesh through the vaginal epithelium has been one of the most common complications with the Cochrane Review reporting an overall erosion rate of 10%.³¹ At least half of mesh exposures are symptomatic and require reoperation for treatment.

As a result of the type of U.S. Food and Drug Administration (FDA) approval transvaginal mesh kits received, the high number of complications encountered in a relatively short time, and the lack of superior clinically significant prolapse symptom outcomes, the FDA issued a Public Health Notice in 2008 and a Safety Communication in 2011. These documents state that "serious complications associated with surgical mesh for transvaginal repair of POP are not rare" and "it is not clear that transvaginal POP repair with mesh is more effective than traditional non-mesh repair" and makes recommendations for the physician (Box 2). The FDA has reclassified how these procedure kits will be approved for use and is requiring additional outcome data before FDA approval. As a result, some mesh prolapse kits in which a trocar passed through the obturator foramen were voluntarily withdrawn from the market. The prepackaged vaginal mesh kits currently available attach mesh mainly to the sacrospinous ligament. Given the uncertain future of transvaginal mesh



and the variety of brands and techniques available, we do not describe a specific technique.

Many experts believe that a role for transvaginal mesh exists given the risk of recurrent prolapse after native tissue repairs. The American College of Obstetricians and Gynecologists and the American Urogynecology Society recommend the following³⁴: 1) POP vaginal mesh repair should be reserved for high-risk individuals in whom the benefit of mesh placement may justify the risk such as individuals with recurrent prolapse (particularly of the anterior compartment) or with medical comorbidities that preclude more invasive and lengthier open and endoscopic procedures; 2) surgeons placing vaginal mesh should undergo training specific to each device and have experience with reconstructive surgical procedures and a thorough understanding of pelvic anatomy; 3) compared with existing mesh products and devices, new

products should not be assumed to have equal or improved safety and efficacy unless long-term clinical data are available; and 4) patients should provide their informed consent after reviewing the risks and benefits of the procedure and after discussing alternative repairs.

Long-term outcome data after mesh-augmented and native tissue vaginal repairs are lacking and what are available demonstrate the need for improved outcomes and fewer complications. This can only be achieved with adequately powered randomized controlled trials with long-term outcomes that include prolapse symptoms and anatomic and functional outcomes.

ABDOMINAL SACRAL COLPOPEXY

Techniques

Abdominal sacral colpopexy can be performed through a laparotomy or by laparoscopy or robot-assisted laparoscopy. Although the surgical approach may be

Box 2. U.S. Food and Drug Administration Recommendations Regarding the Placement of Transvaginal Mesh for Prolapse

Training

- Obtain specialized training for each mesh placement technique and be aware of the risks of surgical mesh.

Patient Selection

- Recognize that, in most cases, pelvic organ prolapse can be treated successfully without mesh, thus avoiding the risk of mesh-related complications.
- Choose mesh surgery only after weighing the risks and benefits of surgery with mesh compared with all surgical and nonsurgical alternatives.
- Consider these factors before placing surgical mesh:
 - Surgical mesh is a permanent implant that may make future surgical repair more challenging.
 - Having a mesh surgery may put the patient at risk for requiring additional surgery or for the development of new complications.
 - Removal of mesh as a result of mesh complications may involve multiple surgeries and significantly impair the patient's quality of life. Complete removal of mesh may not be possible and may not result in complete resolution of complications, including pain.
 - Mesh placed abdominally for prolapse repair may result in lower rates of mesh complications compared with transvaginal prolapse surgery with mesh.

Informing Your Patient

- Inform patients that implantation of surgical mesh is permanent and that some complications associated with the implanted mesh may require additional surgery that may or may not correct the complication.
- Inform patients about the potential for serious complications and their effect on quality of life, including pain during sexual intercourse, scarring, and narrowing of the vaginal wall in prolapse repair.
- Inform the patient about the benefits and risks of nonsurgical options, nonmesh surgery, surgical mesh placed abdominally and the likely success of these alternatives compared with transvaginal surgery with mesh.
- Notify the patient if mesh will be used in her prolapse surgery and provide the patient with information about the specific product used.
- Ensure that the patient understands the postoperative risks and complications of mesh surgery as well as limited long-term outcomes data.
- Provide patients with a copy of the patient labeling from the surgical mesh manufacturer if available.

Modified from U.S. Food and Drug Administration. FDA safety communication: update on serious complications associated with transvaginal placement of surgical mesh for pelvic organ prolapse. Available at: <http://www.fda.gov/MedicalDevices/Safety/AlertsandNotices/ucm262435.htm>. Retrieved December 20, 2012.



different, the steps of the procedure should remain the same. Sacral colpopexy, which is suspension of the vagina to the sacral promontory using a bridging graft through the abdominal approach, is an effective treatment for uterovaginal and vaginal apex prolapse. Many different materials have been used as a graft in sacral colpopexy, including biologic materials (fascia lata, rectus fascia, dura mater) and synthetic materials (polypropylene mesh, polyester fiber mesh, polytetrafluoroethylene mesh, Dacron mesh, and Silastic silicone rubber). Large-pore, lightweight polypropylene mesh is most commonly used and likely has fewer complications compared with other synthetics because of its monofilament and macroporous characteristics.

A randomized trial comparing objective anatomic outcomes after sacral colpopexy performed with cadaveric fascia lata and polypropylene mesh noted polypropylene mesh to be superior to fascia lata in terms of POP-Q points, POP-Q stage, and objective anatomic failure rates at 1 and 5 years after surgery.^{36,37}

The technique of abdominal sacral colpopexy using graft placement is as follows: 1) the patient should be placed in low lithotomy using Allen stirrups so that the surgeon has digital access to the vagina during the operation. A sponge stick or end-to-end anastomosis sizer can be placed in the vagina for manipulation of the apex. A Foley catheter is placed into the bladder for drainage. See Box 3 for tips for minimally invasive sacral colpopexy; 2) intraperitoneal access is gained using laparoscopic or robotic

cannula placement as shown in Figure 7A and B. The small bowel is placed or packed into the upper abdomen, and the sigmoid colon is deviated to the left pelvis as much as possible. The ureters are identified bilaterally for their entire course; 3) attention is turned to the sacrum. The aortic bifurcation, the common and internal iliac vessels, the sigmoid colon, and the right ureter are identified so that these structures can be avoided (Fig. 8B). The left common iliac vein is medial to the left common iliac artery and is particularly vulnerable to damage during this procedure. A longitudinal incision is made in the peritoneum over the sacral promontory; 4) the bony sacral promontory and anterior longitudinal ligament are directly visualized for approximately 4 cm by using blunt and sharp dissection through the subperitoneal fat. We take special care to avoid the delicate plexus of presacral veins that are often present, especially as one dissects more caudally. The middle sacral artery and vein should be identified (Fig. 8B) and avoided; 5) dissection of the peritoneum and subperitoneal fat caudally may be used to create a subperitoneal tunnel into the cul-de-sac so that the graft can be covered with peritoneum after attaching it to the sacrum. Alternatively, the incision over the sacral promontory can be extended toward the vaginal apex sharply. During these processes, the rectum and right ureter are visualized at all times and the course of the dissection is located between these structures; 6) the vagina is elevated cephalad using a sponge stick or end-to-end anastomosis sizer (also known as an

Box 3. Tips for Performing Minimally Invasive Sacral Colpopexy

- Patient positioning is critical.
 - Place egg crate or other antislip device directly below patient to prevent movement during the operation.
 - Position buttocks slightly beyond end of table so vaginal manipulation is possible.
 - Both arms are tucked and protected.
 - Once intra-abdominal access is gained, steep Trendelenburg positioning helps move the small bowel into the upper abdomen.
- Two knowledgeable assistants are necessary:
 - One works intra-abdominally and helps with retraction.
 - One works vaginally and manipulates the vagina and rectum to optimize visualization.
- Side-dock the robot, either parallel or at a 45° angle to the table.
- Placement of ports is integral to procedure success (Fig. 7A–B).
- Assure there is enough space between the robot arms to prevent collision.
- If the colon is redundant, an epiploica can be sutured temporarily to the left anterior abdominal wall to improve visualization.
- If hysterectomy is planned, a supracervical hysterectomy should be considered because the cervix may help to decrease future mesh erosions. Alternatively, a vaginal hysterectomy can be performed before a laparoscopic repair.
- Given the lack of tactile feedback in robotic surgery, identification of the sacral promontory can be challenging. Using laparoscopy initially, this area can be identified and marked with cautery before docking the robot.
- Care should be taken to avoid the intervertebral disc while placing the sacral sutures. Deep stitches through the disc and periosteum should be avoided as cases of osteomyelitis have been reported after robotic sacral colpopexy.
- A barbed suture can be used to close the peritoneum.
- Convert to laparotomy when necessary. Patient safety is of utmost importance.



Box 4. Answers to Key Questions About Treating Pelvic Organ Prolapse

Is the patient sexually active and is she interested in having vaginal intercourse in the future?

If the patient is or plans to be sexually active, a prolapse repair with apical suspension is appropriate. If the patient is older and is no longer sexually active and does not have plans to have vaginal intercourse in the future, an obliterative procedure may be offered. Although these procedures significantly narrow and shorten the vagina, they have a very low rate of prolapse recurrence and are associated with a high rate of patient satisfaction.²⁹ Consent of an informed patient is important in this situation.

If the uterus is present, should a hysterectomy be done at the time of her prolapse repair?

Most prolapse operations intended to suspend the vaginal apex can be done with or without hysterectomy, although some important modifications are sometimes necessary. Uterine-sparing procedures are not appropriate for women with a history of cervical dysplasia, abnormal or postmenopausal bleeding, or those who are at high risk for uterine malignancy. It is reasonable to discuss the issue of concurrent hysterectomy with affected patients before surgery for prolapse, including pertinent risks and benefits, and allow her to share in the decision.

Should the prolapse repair be done through the transvaginal or abdominal route and, if abdominally, should it be done using laparotomy, laparoscopy, or robotic assistance?

The surgical approach to prolapse repair can vary and several choices may be appropriate for any specific patient. Extent and type of prolapse, surgical history, concurrent pathology (eg, ovarian mass, rectal prolapse), age, health status, surgeon experience, and patient preference are important considerations when making this decision. Few studies actually show superiority of one surgery over another for vaginal apex prolapse repair. The Cochrane Review noted that abdominal sacral colpopexy results in fewer apical prolapse recurrences and fewer cases of dyspareunia but has longer operating times and higher costs.¹¹ However, overall reoperation rates (for recurrences and complications) may not be that much different between these surgeries.¹²

Individual surgeon experience, especially for vaginal, laparoscopic, and robotic surgery, is an important predictor of successful outcome. Regarding the recent increase in robot use to assist prolapse surgery, it is often done as physician, patient, or both preference although data are still preliminary supporting its use.

Within reason, an informed patient may influence the route and type of prolapse surgery by preferring one route over another after careful consideration of the advantages and disadvantages of each type of repair. The surgeon could then use this information in the consent process to agree with the patient on the best route of surgery for her particular disease and circumstances.

(continued)

Box 4. Answers to Key Questions About Treating Pelvic Organ Prolapse (continued)

Can the prolapse surgery be done by repairing the patient's own native tissues or is a graft necessary to suspend the apex or other segments of the vaginal walls?

A graft is necessary to correctly perform a sacral colpopexy. For transvaginal repairs, this question has not been answered adequately by research studies and opposing opinions exist among experts. Given the increased risk of graft exposure and lack of long-term data, it may be reasonable to reserve these operations for women at highest risk for prolapse recurrence: those with a previous failed repair and those with severe prolapse.

Is a concurrent procedure to correct overt or occult stress urinary incontinence necessary?

De novo stress urinary incontinence occurs when a previously continent patient develops symptoms of stress urinary incontinence after prolapse repair. These symptoms are extremely bothersome for a patient and are not uncommon. Adding an anti-incontinence procedure at the time of prolapse repair significantly reduces the incidence of later stress urinary incontinence.^{11,12} Before surgery, having the patient perform a standing, cough stress test with a full bladder while the prolapse is reduced (with large swabs, a pessary, or other instrument) may help predict who will best benefit from an anti-incontinence procedure.¹²

Should I refer this surgery to a specialist in Female Pelvic Medicine and Reconstructive Surgery?

The answer to this question will vary greatly depending on surgeon confidence, surgical training and experience, and the availability of urogynecology specialists. In cases of recurrent prolapse, complex urinary and fecal functional symptoms, severe prolapse, and other complex situations, referral may be prudent. In complex cases when referral is not possible as a result of geographical and insurance restrictions, working with a urologist or colorectal surgeon may be helpful.

“EEA sizer”), the peritoneum over the vaginal apex is incised transversely, and the bladder dissected from the anterior vaginal wall sharply for approximately 4 cm or until the entire defect is exposed (Fig. 8A). If this plane is difficult to establish, the bladder can be retrograde filled with fluid to delineate its border; 7) the peritoneum over the posterior vaginal wall into the cul de sac is incised and dissected for 4–6 cm or until the entire defect is exposed. If it is difficult to delineate the rectum, a second end-to-end anastomosis sizer can be placed in the rectum. Manipulating the end-to-end anastomosis sizers in the vagina and rectum so that the tips are apart can define the rectovaginal septum. This may assist in finding the areolar tissue, which is easiest and safest to dissect. Some experts recommend dissection to the perineal body. We prefer to reserve this for

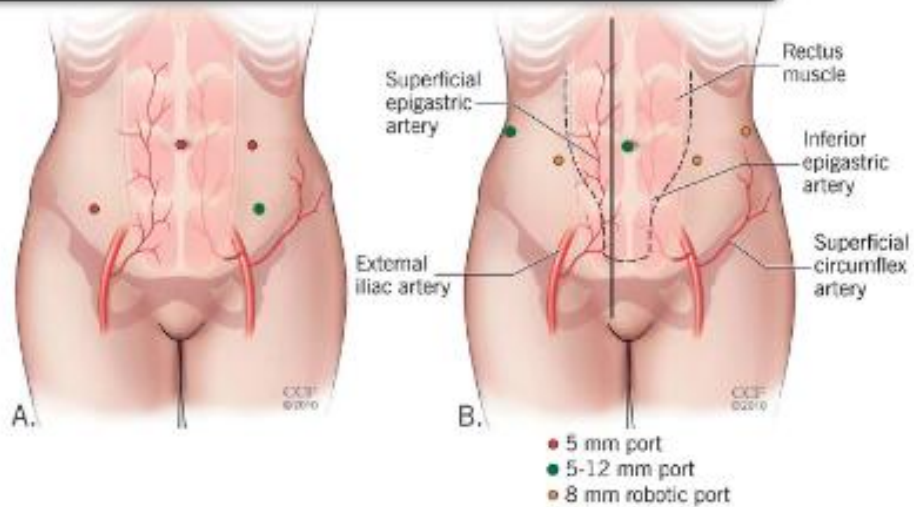


Fig. 7. Port placement for minimally invasive sacral colpopexy. **A.** Operative laparoscopy. **B.** Robot-assisted laparoscopy. Illustration by Ross Pappalardo. Reprinted with permission, Cleveland Clinic Center for Medical Art & Photography © 2010–2012. All rights reserved.

Walters. *Surgical Treatment of Vaginal Apex Prolapse. Obstet Gynecol* 2013.

women with rectal prolapse or severe defecatory dysfunction, because a permanent graft in the distal vagina can be problematic and does not increase symptomatic improvement for the average patient. We routinely evaluate the distal posterior vagina after sacral colpopexy and use a native tissue repair if indicated; 8) a graft is prepared. We recommend a lightweight polypropylene mesh. If this comes in a sheet, two strips measuring 4×15 cm can be created. Alternatively, a prefabricated “Y mesh” can be used. The graft is attached to the posterior vaginal wall with 5–8 nonabsorbable No. 0 or 2-0 sutures 1–2 cm apart. Sutures are placed

through the full fibromuscular thickness of the vaginal wall but not into the vaginal lumen. The graft should extend approximately halfway down the length of the posterior vaginal wall (Figs. 8C and 9); 9) a second piece of graft is attached to the proximal anterior vaginal wall in a similar fashion. Delayed absorbable sutures are used for the most distal stitches on this compartment given the proximity to the bladder and the potential for suture erosion (Figs. 8C and 9); 10) the vagina is elevated with the end-to-end anastomosis sizer and deviated toward the sacral promontory. The appropriate amount of vaginal elevation should

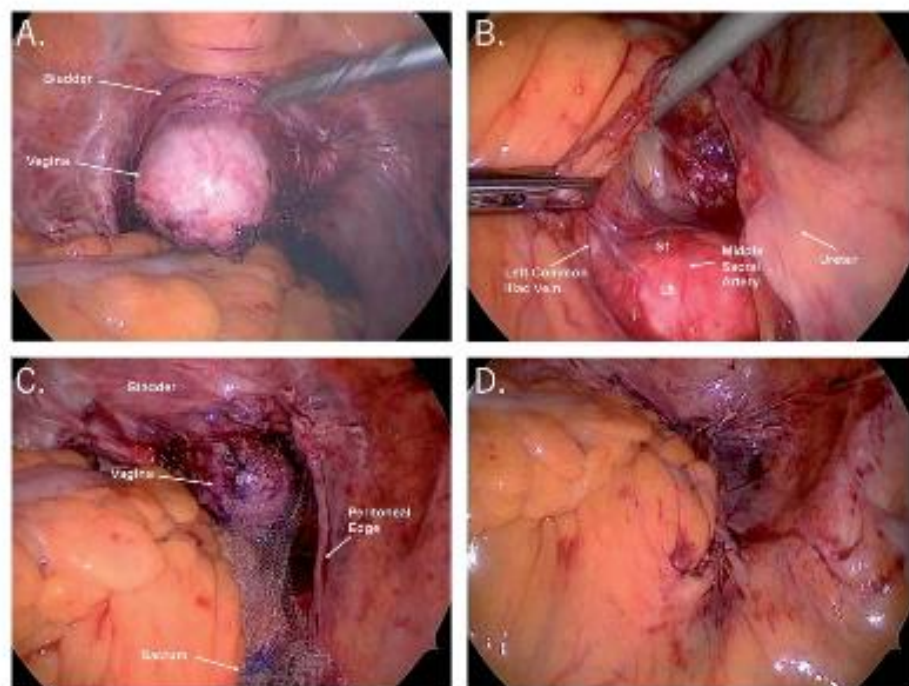


Fig. 8. **A.** The bladder and rectum have been dissected from the vagina. A vaginal probe pushing upward provides shape and stability to the vagina during this process. **B.** This view of the sacral promontory demonstrates where the mesh will be attached and the proximity to vital structures. **C.** The polypropylene mesh has been attached to the anterior and posterior vaginal walls as well as the sacral promontory. **D.** The peritoneum is closed over the graft.

Walters. *Surgical Treatment of Vaginal Apex Prolapse. Obstet Gynecol* 2013.

provide full apical support without undue tension on the vagina. The graft should be trimmed to the appropriate length. Using a stiff but small half-curved tapered needle with permanent No. 0 suture, two to four sutures are used to attach the mesh to the anterior longitudinal ligament of the sacrum (Fig. 9); 11) the peritoneum is then closed over the exposed graft with absorbable suture (Fig. 8D); 12) a Burch colposuspension or other anti-incontinence procedure, if planned, is completed. Cystoscopy is performed after the administration of indigo carmine to evaluate bladder integrity and to verify ureteral patency; and 13) posterior colporrhaphy and perineoplasty are performed if needed to treat the remaining rectocele and perineal defect.

Outcomes

A review of abdominal sacral colpopexy noted the success rate when defined as lack of apical prolapse postoperatively ranging from 78–100%.³⁸ The median reoperation rates for POP and for stress urinary incontinence in the studies that reported these outcomes were 4.4% (range 0–18.2%) and 4.9% (range 1.2–30.9%), respectively. A randomized controlled trial of sacral colpopexy with and without concomitant Burch colposuspension had reassuring anatomic outcomes at 2-year follow-up with 95% of patients having excellent objective outcomes for the vaginal apex (within 2 cm of total vaginal length), 2% demonstrating stage III prolapse, and 3% undergoing reoperation for prolapse.³⁹ These patients also demonstrated improved urinary, defecatory, and sexual function based on validated questionnaires. A long-term study, in which patients who had undergone sacral colpopexy at least 10 years prior were contacted and asked about prolapse symptoms and reoperations, demonstrated that even graft-augmented repairs deteriorate over time. At an average of 14-year follow-up, sacral colpopexy had a 26% failure rate based on reoperation (10.5%) and prolapse symptoms (16%).⁴⁰ The Cochrane Review showed that, based on three randomized trials against sacrospinous ligament colpopexy, abdominal sacral colpopexy had a lower rate of recurrent apical prolapse and less postoperative dyspareunia but longer operating time and higher cost.³¹

Complications

Intraoperative complications during sacral colpopexy are uncommon but can be life-threatening. Most complications reported after sacral colpopexy tend to be similar to those of other abdominal operations, including hemorrhage, enterotomy, ureteral damage, cystotomy, proctotomy, and extr fascial wound infections. Complications unique to minimally invasive

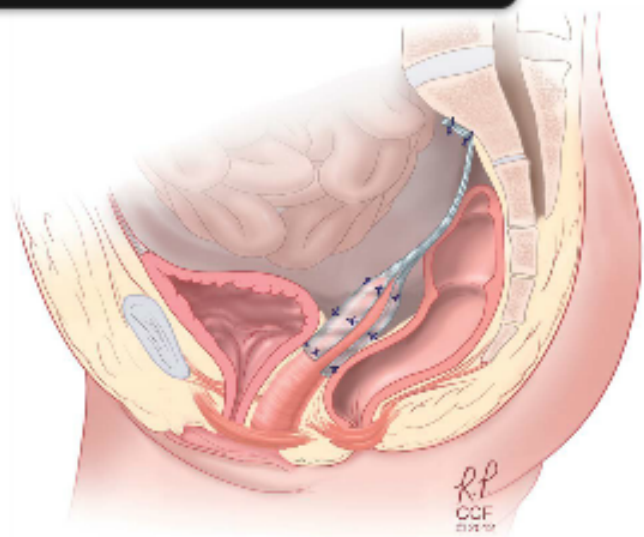


Fig. 9. Lateral view of completed sacral colpopexy with graft attaching the anterior and posterior vagina to the sacral promontory. Illustration by Ross Papalardo. Reprinted with permission, Cleveland Clinic Center for Medical Art & Photography © 2010–2012. All rights reserved.

Walters. *Surgical Treatment of Vaginal Apex Prolapse*. *Obstet Gynecol* 2013.

sacral colpopexy include corneal abrasion, extensive subcutaneous emphysema, and hypercarbia. The steep Trendelenburg positioning and long operative times are thought to contribute to these complications. Life-threatening bleeding from the presacral space is one of the most feared complications of sacral colpopexy. When there is bleeding from presacral vessels, hemostasis can be difficult to achieve because of the complex interlacing of the venous network both beneath and on the surface of the sacral periosteum. When these veins have been damaged, they can retract beneath the bony surface of the anterior sacrum and recede into the underlying channels of cancellous bone. Communications with adjacent pelvic veins, especially the left common iliac vein, can be particularly troublesome. If direct pressure and packing fails to control the bleeding, sutures, metallic clips, cautery, and bone wax should be used. If these measures are not successful, sterilized stainless steel thumbtacks can be placed on the retracted bleeding presacral vein to treat life-threatening hemorrhage.

Longer-term postoperative complications include small bowel obstruction, hernia, and erosion of implanted materials. The median rate of small bowel obstruction requiring surgery has been reported as 1.1% (range 0.6–8.6%), which is similar to the rate of small bowel obstruction encountered in prospective studies.³⁸ Although rare, nerve injuries and sacral osteomyelitis have been reported.³⁸



The most common long-term complication is erosion of synthetic mesh or suture through the vagina, which occurs in 6% of cases at 2-year follow-up.³⁹ This rate is likely underestimated, because most studies do not have long enough follow-up or routine examinations designed to evaluate this complication. Cigarette smoking and concurrent hysterectomy each increase the risk of mesh erosion by an odds ratio of 5.⁴¹ When mesh erosions are encountered, conservative treatment with vaginal estrogen should be a first-line treatment. If the patient is asymptomatic, observation can be considered. However, most patients with this complication require partial removal of the mesh and closure of the defect in the vagina.

SURGICAL APPROACHES: VAGINAL COMPARED WITH LAPAROTOMY, LAPAROSCOPY, AND ROBOT

To date, there is little scientific evidence available to base the decision on which route of surgery to perform for advanced uterovaginal or posthysterectomy vaginal vault prolapse. There are three randomized controlled trials to date comparing abdominal sacral colpopexy with sacrospinous ligament suspension,⁴²⁻⁴⁴ which have varying definitions of surgical success. The Cochrane Database Review³¹ noted abdominal sacral colpopexy to be associated with lower rates of recurrent apical prolapse and dyspareunia than the vaginal sacrospinous colpopexy. These benefits must be balanced against a longer operating time, longer time to return to activities of daily living, and increased cost of the abdominal approach.

Minimally invasive sacral colpopexy includes conventional laparoscopy and robot-assisted laparoscopy. Cohort studies demonstrate similar anatomic, objective, and subjective outcomes among all approaches.⁴⁵⁻⁴⁷ To date, one randomized controlled trial exists comparing outcomes between the conventional laparoscopic and the robot-assisted laparoscopic approach.⁴⁸ Sacral colpopexy with robot-assisted laparoscopy demonstrated increased operative times and cost as well as increased pain and pain medication use in the first 6 weeks compared with conventional laparoscopy.

Although robot assistance may not have an advantage over conventional laparoscopy in the hands of expert laparoscopists, it has allowed many surgeons to offer minimally invasive sacral colpopexy, which is associated with faster recoveries and shorter hospital stays compared with laparotomy. Additional well-designed studies are needed to clarify the robot's role in sacral colpopexy.

The surgical approach to prolapse repair can vary and several choices may be appropriate for any specific patient. Extent and type of prolapse, surgical history, concurrent pathology (eg, ovarian mass, rectal prolapse), age, health status, surgeon experience, and patient preference are important to consider when making this decision. Individual surgeon experience, especially for vaginal, laparoscopic, and robotic surgery, is an important predictor of successful outcome. For example, performance of laparoscopic hysterectomy by experienced high-volume surgeons at high-volume hospitals is associated with less blood loss, fewer adverse events, and lower costs.^{49,50} Regarding the recent increase in robot use to assist prolapse surgery, it is often done as physician preference although data are still preliminary supporting its use.

Special surgical considerations related to the patient's preferences occasionally influence the route of prolapse surgery. Within reason, an informed patient may influence the route and type of prolapse surgery by preferring one route over another after careful consideration of the advantages and disadvantages of each type of repair.⁵¹ The surgeon could then use this information in the consent process to agree with the patient on the best route of surgery for her particular disease and circumstances.

UTERINE PRESERVATION DURING SURGERY FOR UTEROVAGINAL PROLAPSE

Hysterectomy is done almost routinely in the United States at the beginning of all surgical repairs for uterine and uterovaginal prolapse. Often, uterine preservation in women with uterovaginal prolapse is only considered if future fertility is desired. However, there has been a recent questioning of this practice in the United States, especially because gynecologists (and patients) in many other countries do not routinely prefer hysterectomies in prolapse repairs. More women are requesting uterine preservation for many other reasons, including issues of sexuality, body image, cultural preferences, and the concern for earlier-onset menopause after hysterectomy.

Vaginal, abdominal, and laparoscopy techniques for hysteropexy have all been described, although many questions related to hysteropexy remain unanswered. A review on this topic by Ridgeway et al⁵² concluded that uterine preservation during surgery for uterovaginal prolapse may be an option in appropriately selected women who desire it, although prospective randomized trials are needed to corroborate this. Studies have reported reassuring results with laparoscopic suture hysteropexy^{53,54} and sacrospinous





hysteropexy.^{50,51} Most procedures that aim to suspend the vaginal apex described in this article can be done with or without hysterectomy, although some important modifications are sometimes necessary. Although the risk of unanticipated pathology in asymptomatic women with prolapse is very low,⁴⁷ uterine-sparing procedures are not appropriate for women with a history of cervical dysplasia, abnormal uterine bleeding, postmenopausal bleeding, or those who are at high risk for uterine malignancy. Patients should be counseled that evaluation and management of these problems may be more difficult after uterine-sparing prolapse repairs.

SUMMARY AND FUTURE DIRECTIONS

The prevalence of vaginal prolapse appears to be increasing. Because the prevalence of POP increases with age, the changing demographics of the world's population will result in even more affected women. Demographic studies project that by 2050, 58.2 million women will have at least one pelvic floor disorder, including 41.3 million with urinary incontinence and 9.2 million with prolapse.² This would result in approximately 310,000 stress urinary incontinence procedures and 246,000 prolapse operations annually.⁵⁸

Over the last 25 years, the field of female pelvic medicine and reconstructive surgery has evolved significantly. Thanks to continued research efforts, our understanding of pathogenesis, risk factors, and treatment outcomes of pelvic floor disorders has progressed considerably. This has culminated in a newly organized subspecialty within the American Board of Obstetrics and Gynecology and American Board of Urology, which aims to continue to provide education and sound scientific data to respond to the many unanswered questions that remain in this field.

Although a board-certified subspecialty increases the likelihood that a woman seeking treatment for POP will be offered valid treatment options, many women will not have access to subspecialty care. Given the staggering projections of pelvic floor disorders, many generalist obstetrician-gynecologists will be caring for these women. What these surgeons will offer to women will depend on surgical training and experience, confidence, and geographic location. Given that vaginal apex support contributes significantly to the support of all segments, it will be critical that surgeons who perform surgical repair of POP are comfortable and proficient with vaginal apex suspensions as described in this article. In cases of recurrent prolapse, transvaginal mesh complications, complex urinary and fecal functional symptoms, and severe

prolapse, referral to a surgical subspecialist may be prudent.

The increased prevalence of prolapse also is probably a result of inadequate recognition and repair of pelvic organ support defects when pelvic surgery has already been performed. The standard use of cul-de-sac obliteration and uterosacral ligament suspension to provide appropriate support of the vaginal apex at the time of hysterectomy for other indications would most likely decrease the incidence of later enterocele and posthysterectomy vaginal apex prolapse.

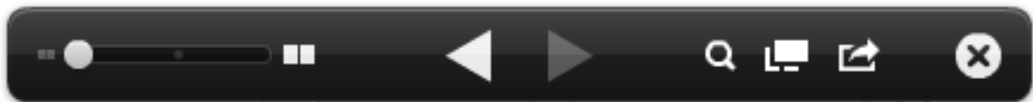Efforts to decrease recurrences after prolapse surgeries are paramount to improving care to our patients. We suggest using transvaginal apical repairs for older patients, those with primary and less severe prolapse, and those with comorbidities that might increase surgical risk. Younger women, those with more severe prolapse or recurrences after vaginal surgery, and women with prolapsed, short vaginas might benefit from sacral colpopexy with mesh, preferably by a minimally invasive route. If the patient is older and no longer sexually active and does not desire to have vaginal intercourse in the future, a vaginal obliterative procedure may be appropriate and is very effective. More education and research into the understanding of the anatomy of pelvic support and the pathogenesis of prolapse and in the principles of pelvic and vaginal reconstructive surgery are needed to improve care to all affected women. More high-quality comparative surgical trials are badly needed as is more information about the pros and cons of surgical innovations such as vaginal grafts and the use of the surgical robot.

REFERENCES

1. Boyles SH, Weber AM, Meyn L. Procedures for pelvic organ prolapse in the United States, 1979-1997. *Am J Obstet Gynecol* 2003;188:108-15.
2. Wu JM, Hundley AF, Fulton RG, Myers ER. Forecasting the prevalence of pelvic floor disorders in US women: 2010 to 2050. *Obstet Gynecol* 2009;114:1278-83.
3. Bump RC, Norton PA. Epidemiology and natural history of pelvic floor dysfunction. *Obstet Gynecol Clin North Am* 1998;25:723-46.
4. Mant J, Painter R, Vessey M. Epidemiology of genital prolapse observations from the Oxford Family Planning Association Study. *Br J Obstet Gynaecol* 1997;104:579-85.
5. Hendrix SL, Clark A, Nygaard I, Aragaki A, Barnabei V, McTiernan A. Pelvic organ prolapse in the Women's Health Initiative: gravity and gravidity. *Am J Obstet Gynecol* 2002;186:1160-6.
6. Chen L, Ashton-Miller JA, Hsu Y, DeLancey JO. Interaction among apical support, levator ani impairment, and anterior vaginal wall prolapse. *Obstet Gynecol* 2006;108:324-32.



7. Jelovsek JE, Maher C, Barber MD. Pelvic organ prolapse. *Lancet* 2007;369:1027-38.
8. Barber MD, Neubauer NL, Klein-Olarte V. Can we screen for pelvic organ prolapse without a physical examination in epidemiologic studies? *Am J Obstet Gynecol* 2006;195:942-8.
9. Bump RC, Mattiasson A, Bo K, Brubaker LP, DeLancey JO, Klarskov P, et al. The standardization of terminology of female pelvic organ prolapse and pelvic floor dysfunction. *Am J Obstet Gynecol* 1996;175:10-7.
10. Haylen BT, de Ridder D, Freeman RM, Swift SE, Berghmans B, Lee J, et al; International Urogynecological Association; International Continence Society. An International Urogynecological Association (IUGA)/International Continence Society (ICS) joint report on the terminology for female pelvic floor dysfunction. *NeuroUrol Urodyn* 2010;29:4-20.
11. Brubaker L, Cundiff GW, Fine P, Nygaard I, Richter HE, Visco AG, et al; Pelvic Floor Disorders Network. Abdominal sacrocolpopexy with Burch colposuspension to reduce urinary stress incontinence. *N Engl J Med* 2006;354:1557-66.
12. Wei JT, Nygaard I, Richter HE, Nager CW, Barber MD, Kenton K, et al; Pelvic Floor Disorders Network. A midurethral sling to reduce incontinence after vaginal prolapse repair. *N Engl J Med* 2012;366:2358-67.
13. Culligan PJ. Nonsurgical management of pelvic organ prolapse. *Obstet Gynecol* 2012;119:852-60.
14. Ismail SI, Bain C, Hagen S. Oestrogens for treatment or prevention of pelvic organ prolapse in postmenopausal women. *The Cochrane Database of Systematic Reviews* 2010, Issue 9. Art. No.: CD007063. DOI: 10.1002/14651858.CD007063.pub2.
15. Antibiotic prophylaxis for gynecologic procedures. ACOG Practice Bulletin No. 104. American College of Obstetricians and Gynecologists. *Obstet Gynecol* 2009;113:1180-9.
16. Clarke-Pearson DL, Abaid LN. Prevention of venous thromboembolic events after gynecologic surgery. *Obstet Gynecol* 2012;119:155-67.
17. Gøenaga KF, Matos D, Wille-Jørgensen P. Mechanical bowel preparation for elective colorectal surgery. *The Cochrane Database of Systematic Reviews* 2011, Issue 9. Art. No.: CD001544. DOI: 10.1002/14651858.CD001544.pub4.
18. Cruikshank SH, Kovac SR. Randomized comparison of three surgical methods used at the time of vaginal hysterectomy to prevent posterior enterocele. *Am J Obstet Gynecol* 1999;180:859-65.
19. Kasturi S, Bentley-Taylor M, Woodman PJ, Terry CL, Hale DS. High uterosacral ligament vaginal vault suspension: comparison of absorbable vs permanent suture for apical fixation. *Int Urogynecol J* 2012;23:941-5.
20. Abbasy S, Kenton K. Obliterative procedures for pelvic organ prolapse. *Clin Obstet Gynecol* 2010;53:86-98.
21. Sze EH, Karram MM. Transvaginal repair of vault prolapse: a review. *Obstet Gynecol* 1997;89:466-75.
22. Webb MJ, Aronson MP, Ferguson LK, Lee RA. Posthysterectomy vaginal vault prolapse: primary repair in 693 patients. *Obstet Gynecol* 1998;92:281-5.
23. Paraiso MF, Ballard LA, Walters MD, Lee JC, Mitchinson AR. Pelvic support defects and visceral and sexual function in women treated with sacrospinous ligament suspension and pelvic reconstruction. *Obstet Gynecol* 1996;175:1423-30.
24. Shull BT, Capen CV, Riggs MW, Kuehl TJ. Bilateral attachment of the vaginal cuff to ileococcygeus fascia: an effective method of cuff suspension. *Am J Obstet Gynecol* 1993;168:1669-74.
25. Meeks GR, Washburne JF, McGeher RP, Wiser WL. Repair of vaginal vault prolapse by suspension of the vagina to ileococcygeus (prespinous) fascia. *Am J Obstet Gynecol* 1994;171:1444-52.
26. Maher CF, Murray CJ, Carey MP, Dwyer PL, Ugoni AM. Iliococcygeus or sacrospinous fixation for vaginal vault prolapse. *Obstet Gynecol* 2001;98:40-4.
27. Shull BL, Bachofen C, Coates KW, Kuehl TJ. A transvaginal approach to repair of apical and other associated sites of pelvic organ prolapse with uterosacral ligaments. *Am J Obstet Gynecol* 2000;183:1365-73.
28. Margulies RU, Rogers MA, Morgan DM. Outcomes of transvaginal uterosacral ligament suspension: systematic review and metaanalysis. *Am J Obstet Gynecol* 2010;202:124-34.
29. Barber MD, Amundsen CL, Paraiso MF, Weidner AC, Romero A, Walters MD. Quality of life after surgery for genital prolapse in elderly women: obliterative and reconstructive surgery. *Int Urogynecol J Pelvic Floor Dysfunct* 2007;18:799-806.
30. DeLancey JO, Morley GW. Total colpocleisis for vaginal eversion. *Am J Obstet Gynecol* 1997;176:1228-32.
31. Maher CM, Feiner B, Baessler K, Glazener CM. Surgical management of pelvic organ prolapse in women: the updated summary version Cochrane Review. *Int Urogynecol J* 2011;22:1445-57.
32. Diwadkar GB, Barber MD, Feiner B, Maher C, Jelovsek JE. Complication and reoperation rates after apical vaginal prolapse surgical repair: a systematic review. *Obstet Gynecol* 2009;113:367-73.
33. Altman D, Väyrynen T, Engh ME, Axelsen S, Falconer C; Nordic Transvaginal Mesh Group. Anterior colporrhaphy versus transvaginal mesh for pelvic-organ prolapse. *N Engl J Med* 2011;364:1826-36.
34. Vaginal placement of synthetic mesh for pelvic organ prolapse. Committee Opinion No. 513. American College of Obstetricians and Gynecologists. *Obstet Gynecol* 2011;118:1459-64.
35. U.S. Food and Drug Administration. Available at: <http://www.fda.gov/medicaldevices/safety/alertsandnotices/nem262435.htm>. Retrieved November 20, 2012.
36. Culligan PJ, Blackwell L, Goldsmith LJ, Graham CA, Rogers A, Heit MH. A randomized controlled trial comparing fascia lata and synthetic mesh for sacral colpopexy. *Obstet Gynecol* 2005;106:29-37.
37. Tate SB, Blackwell L, Lorenz DJ, Steptoe MM, Culligan PJ. Randomized trial of fascia lata and polypropylene mesh for abdominal sacrocolpopexy: 5-year follow-up. *Int Urogynecol J* 2011;22:137-43.
38. Nygaard IE, McCreery R, Brubaker L, Connolly A, Cundiff G, Weber AM, et al Pelvic floor disorders network. Abdominal sacrocolpopexy: a comprehensive review. *Obstet Gynecol* 2004;104:805-23.
39. Brubaker L, Nygaard I, Richter HE, Visco A, Weber AM, Cundiff GW, et al. Two-year outcomes after sacrocolpopexy with and without Burch to prevent stress urinary incontinence. *Obstet Gynecol* 2008;112:49-55.
40. Hilger WS, Poulson M, Norton PA. Long-term results of abdominal sacrocolpopexy. *Am J Obstet Gynecol* 2003;189:1606-10.
41. Cundiff GW, Varner E, Visco AG, Zyczynski HM, Nager CW, Norton PA, et al; Pelvic Floor Disorders Network. Risk factors for mesh/suture erosion following sacral colpopexy. *Am J Obstet Gynecol* 2008;199:688.e1-5.
42. Benson JT, Lucente V, McClellan E. Vaginal versus abdominal reconstructive surgery for the treatment of pelvic support



defects: a prospective randomized study with long-term outcome evaluation. *Am J Obstet Gynecol* 1996;175:1418-21.

43. Lo T-S, Wang AL. Abdominal colposacropexy and sacrospinous ligament suspension for severe uterovaginal prolapse: a comparison. *J Gynecol Surg* 1998;14:59-64.

44. Maher CF, Qatawneh AM, Dwyer PL, Carey MP, Cornish A, Schluter PJ. Abdominal sacral colpopexy or vaginal sacrospinous colpopexy for vaginal vault prolapse: a prospective randomized study. *Am J Obstet Gynecol* 2004;190:20-6.

45. Paraiso MF, Walters MD, Rackley RR, Melek S, Hugney C. Laparoscopic and abdominal sacral colpopexies: a comparative cohort study. *Am J Obstet Gynecol* 2005;192:1752-8.

46. Geller EJ, Parnell BA, Dunivan GC. Robotic vs abdominal sacrocolpopexy: 44-month pelvic floor outcomes. *Urology* 2012;79:532-6.

47. Siddiqui NY, Geller EJ, Visco AG. Symptomatic and anatomic 1-year outcomes after robotic and abdominal sacrocolpopexy. *Am J Obstet Gynecol* 2012;206:435.e1-5.

48. Paraiso MF, Jelovsek JE, Frick A, Chen CC, Barber MD. Laparoscopic compared with robotic sacrocolpopexy for vaginal prolapse: a randomized controlled trial. *Obstet Gynecol* 2011;118:1005-13.

49. Wallenstein MR, Ananth CV, Kim JH, Burke WM, Hershman DL, Lewin SN, et al. Effect of surgical volume on outcomes for laparoscopic hysterectomy for benign indications. *Obstet Gynecol* 2012;119:709-16.

50. Twijnstra AR, Blikkendaal MD, van Zwet EW, van Kesteren PJ, de Kroon CD, Jansen FW. Predictors of successful surgical outcome in laparoscopic hysterectomy. *Obstet Gynecol* 2012;119:700-8.

51. Surgery and patient choice. ACOG Committee Opinion No. 395. American College of Obstetricians and Gynecologists. *Obstet Gynecol* 2008;111:243-7.

52. Ridgeway B, Frick AC, Walters MD. Hysteropexy. A review. *Minerva Ginecol* 2008;60:509-28.

53. Krause HG, Groh JT, Sloane K, Higgs P, Carey MP. Laparoscopic sacral suture hysteropexy for uterine prolapse. *Int Urogynecol J Pelvic Floor Dysfunct* 2006;17:378-81.

54. Maher CF, Carey MP, Murray CJ. Laparoscopic suture hysteropexy for uterine prolapse. *Obstet Gynecol* 2001;97:1010-4.

55. Maher CF, Cary MD, Slack MC, Murray CJ, Milligan M, Schluter P. Uterine preservation or hysterectomy at sacrospinous colpopexy for uterovaginal prolapse. *Int Urogynecol J* 2001;12:381-4.

56. van Brummen HJ, van de Pol G, Aulderts CI, Heintz AP, van der Vaart CH. Sacrospinous hysteropexy compared to vaginal hysterectomy as primary surgical treatment for a descensus uteri: effects on urinary symptoms. *Int J Urogynecol* 2003;14:350-5.

57. Frick AC, Walters MD, Larkin KS, Barber MD. Risk of unanticipated abnormal gynecologic pathology at the time of hysterectomy for uterovaginal prolapse. *Am J Obstet Gynecol* 2010;202:507.e1-4.

58. Wu JM, Kawasaki A, Hundley AF, Dieter AA, Myers ER, Sung VW. Predicting the number of women who will undergo incontinence and prolapse surgery, 2010 to 2050. *Am J Obstet Gynecol* 2011;205:230.e1-5.



Continuing Medical Education Credits Available for the Clinical Expert Series

Continuing medical education (CME) credits are available for reading the Clinical Expert Series. Visit <http://www.greenjournal.org> and click on the "CME" tab to read the articles and complete their associated quizzes.

ACCME Accreditation

The American College of Obstetricians and Gynecologists is accredited by the Accreditation Council for Continuing Medical Education (ACCME) to provide continuing medical education for physicians.

AMA PRA Category 1 Credit(s)[™]

The American College of Obstetricians and Gynecologists designates this journal-based CME activity for a maximum of 2 *AMA PRA Category 1 Credits*.[™] Physicians should claim only the credit commensurate with the extent of their participation in the activity.

College Cognate Credit(s)

The American College of Obstetricians and Gynecologists designates this journal-based CME activity for a maximum of 2 Category 1 College Cognate Credits. The College has a reciprocity agreement with the AMA that allows *AMA PRA Category 1 Credits*[™] to be equivalent to College Cognate Credits.

© 2011